



LUCERNO DYNAMICS, LLC

140 Towerview Court

Cary, NC 27513

919-371-6800

July 20, 2020

Michael Layton, Director
Division of Materials, Safety, Security, State and Tribal Programs
Office of Nuclear Material Safety and Safeguards
Nuclear Regulatory Commission

Dear Michael,

As you know, on May 18, 2020, pursuant to 10 C.F.R. § 2.802, "Petition for Rulemaking," Lucerno Dynamics, LLC, submitted a petition to amend 10 C.F.R. § 35.2, "Definitions" and 10 C.F.R. § 35.3045, "Report and Notification of a Medical Event."

In this communication, I am providing additional relevant information regarding the need for the NRC to expeditiously grant the petition and eliminate the extravasation exemption policy.

Attached please find an article by Arveschoug et al., *Extravasation of [¹⁷⁷Lu] Lu-DOTATOC: case report and discussion*. I would encourage your team read this case report if they have not done so already and would like to highlight a few points. The authors suggest:

- "As a growing amount of therapeutic injections in nuclear medicine are being performed, there is an increasing need for guidelines regarding extravasations both with respect to prevention and to early and delayed treatment."
- By quickly identifying the extravasation and mitigating it, the patient had a better outcome. Their observation and those from other therapy cases "with and without radiation damage indicate that immediate and efficient treatment is decisive for the outcome after extravasation."

While the authors point out that their patient had not shown tissue reactions immediately or one year after the estimated 6 Gy of absorbed dose to their arm tissue, it is unlikely that adverse tissue reactions would be visible before 2-3 years after the extravasation. This patient should be followed for several more years to ascertain the true extent of tissue damage.

While it is well known that therapeutic extravasations can result in significant tissue doses that exceed medical event reporting limits, we continue to demonstrate that significant diagnostic extravasations can also exceed these same reporting limits. I have attached 13 new cases for you and your team to consider. These cases are incremental to the 23 previously shared cases in the May 18 Petition and show the importance of reporting diagnostic as well as therapeutic extravasations. The dose equivalent to tissue from



significant extravasations is agnostic to the radiopharmaceutical. Diagnostic radiopharmaceuticals, when administered without incident, will result in a very low dose equivalent to tissue. However, as these examples show, a significant diagnostic extravasation into a typical tissue volume, associated with these misadministrations, results in dose equivalent to tissue that exceeds reporting limits and are indicative of specific and generic issues that the NRC should want to address with licensees. For example, the commonly used straight stick injection technique of the bone scan radiopharmaceutical MDP is an example of a problem that is likely affecting thousands of patients every year. When a patient is extravasated during a straight stick injection, MDP remains in a small volume of tissue and results in a high dose equivalent to that tissue. This is one example of why it is important to patient safety that the NRC is made aware of significant extravasations.

In late 2019, the NRC asked Lucerno for information regarding the dosimetry method used to assess the extravasations we have submitted. This method was presented at the SNMMI Mid-Winter Meeting in January 2020, as previously communicated. The method has been refined over the past several months and now also assesses the dose to the overlaying skin. The dosimetry of infiltrated tissue and skin may be assessed using methods forthcoming in a scientific paper recently submitted to the journal *Health Physics*. Authors include physicians and medical physicists, one of whom serves on the SNMMI MIRD Committee. The paper, like the attached article regarding the Lu-DOTATOC extravasation, emphasizes the need to characterize the extravasation (volume infiltrated, activity present, retention, and clearance rates) for dosimetry to assess event severity and guide follow-up response.

The new method may benefit from some slight modifications to the VARSKIN software that would provide VARSKIN6 with additional capability to model and calculate dose to both tissue and the overlaying skin for an injected radiopharmaceutical extravasation. Currently VARSKIN6 handles above-skin contamination, but not irradiation from beneath the skin.

To use VARSKIN in the extravasation mode and to calculate absorbed dose for a 2D region represented by a contiguous circular area of 10 cm^2 , it will be important for the user to:

- 1) select a flat cylindrical source geometry,
- 2) set the source geometry dimensions,
- 3) set the distance from the cylinder to the sensitive basal cell layer, and
- 4) remove the code data files which account for backscatter correction.

In order to minimize the work involved and the variability of infiltration dosimetry calculations for the nuclear medicine community, the VARSKIN code should be modified to implement this configuration as an option. I have copied Vered Shaffer on this communication so there is an awareness within NRC of the potential for VARSKIN to help in calculating the dosimetry of extravasations.



LUCERNO DYNAMICS, LLC

140 Towerview Court
Cary, NC 27513
919-371-6800

Our previously submitted petition cites many reasons why the NRC should address the extravasation exemption. A recently published [white paper](#) by Dr. Darrell Fisher, specialist in the dosimetry and biological effects of internal emitters and former member of the NRC's Advisory Committee for the Medical Use of Isotopes (ACMUI), supports the petition and provides further reasons why the NRC needs to expeditiously correct this reporting inconsistency.

Sincerely,

DocuSigned by:

Ron Lattanze

0C2FCDBE78A7435...

Ron Lattanze
Chief Executive Officer

Enclosure

1. Extravasation of [^{177}Lu] Lu-DOTATOC: case report and discussion
2. An additional 13 cases of dosimetric evidence that diagnostic extravasations can exceed 0.5 Sv dose equivalent to tissue

cc:

Chris Einberg
Lisa Dimmick
Said Daibes
Kellee Jamerson
Donna-Beth Howe
David Crowley
Matt Dennis
Vered Shaffer

CASE REPORT

Open Access



Extravasation of [^{177}Lu]Lu-DOTATOC: case report and discussion

Anne Kirstine Arveschoug¹, Anne Charlotte Bekker¹, Peter Iversen¹, Henrik Bluhme¹, Gerda Elisabeth Villadsen² and Peter Frøhlich Staantum^{1*} 

Abstract

Background: In the case of extravasation of radioactive drugs used in peptide-receptor radionuclide therapy of neuroendocrine tumors, or in radionuclide therapy in general, rapid action is important to reduce or avoid complications. The literature on extravasation of drugs for radionuclide therapy is sparse. Based on the present case, we discuss handling and consequences of extravasation. Further, we demonstrate that dosimetry can aid in judging if the treatment of neuroendocrine tumors is satisfactory even after extravasation.

Case presentation: A case of extravasation of [^{177}Lu]Lu-DOTATOC with a treatment strategy involving exercise and elevation of the affected arm and application of a compression bandage and heating is reported. Redistribution of the drug is verified and quantified by whole-body imaging and quantitative SPECT/CT and measurements of the dose rate at contact with the injection site. [^{177}Lu]Lu-DOTATOC was redistributed to tumors and organs within 1 day. The patient did not report any discomfort during or after hospitalization, and no side effects related to extravasation were observed. Quantitative SPECT/CT scans at the subsequent treatment cycle of the same patient were analyzed for a comparison between the treatments. Dosimetry showed the treatments were similar with respect to the kidney and tumor absorbed doses. The radiation dose to the epidermal basal layer near the injection site was estimated and found to be consistent with the lack of side effects.

Conclusions: The treatment of extravasation was successful, and the redistribution of the drug can be easily verified through measurement of the dose rate at contact with the skin. From the results of dosimetry, it was assessed that no change of the treatment course was necessary to compensate for a possibly incomplete treatment as a result of the extravasation.

Keywords: Extravasation, Peptide-receptor radionuclide therapy (PRRT), Kidney dosimetry, [^{177}Lu]Lu-DOTATOC

Background

The use of peptide-receptor radionuclide therapy (PRRT) of neuroendocrine tumors (NETs) is increasing across the world, not at least since the NETTER trial demonstrated an increased survival when compared to best supportive care including octreotide long-acting repeatable (LAR) [1].

Extravasations of drugs for PRRT or radionuclide therapy in general are rare events. The literature on the

subject is limited, yet valuable, as practical experiences and advice are important in order to take rapid action as soon as an extravasation is realized. In a publication from 2017 by van der Pol and colleagues [2], the consequences of radiopharmaceutical extravasation and possible therapeutic interventions were reviewed with mention of 10 cases of extravasation of therapeutic radiopharmaceuticals—in most cases with the isotope ^{90}Y . More recently cases with ^{177}Lu [3, 4], ^{223}Ra [5], and an additional case with ^{90}Y [6] have been reported. In some cases, little or no medical consequences of extravasation are reported, while in other cases severe skin damage can be observed. To the best of our knowledge, only one

* Correspondence: petstaan@rm.dk

¹Department of Nuclear Medicine and PET-Centre, Aarhus University Hospital, Palle Juul-Jensens Boulevard 165, 8200 Aarhus N, Denmark
Full list of author information is available at the end of the article

other case with extravasation of ^{177}Lu -labelled peptides has been published [3], in spite of the fact that hundreds of daily treatment cycles with ^{177}Lu Lu-DOTATATE and ^{177}Lu Lu-DOTATOC take place in the PRRT setting in NET-centers all over the world today.

In the present work, we describe a case of extravasation of ^{177}Lu Lu-DOTATOC, which was realized shortly after injection. Treatment of the extravasation is described, and documentation of the redistribution as measured by dose rate measurements and quantitative SPECT/CT scans is reported and discussed in relation to the current literature.

Case presentation

A 68-year-old female patient with a progressive midgut neuroendocrine tumor (NET) with liver and intraperitoneal dissemination was scheduled for peptide receptor radionuclide therapy (PRRT) with ^{177}Lu Lu-DOTATOC. Four cycles were planned with standard activity of 7.4 GBq ^{177}Lu Lu-DOTATOC and kidney protection during PRRT with an arginine/lysine mixture according to the EANM guidelines [7].

^{177}Lu Lu-DOTATOC was administered through a peripheral venous catheter placed in the left cubital fossa in the first treatment cycle. After the injection of ^{177}Lu Lu-DOTATOC (7.5 GBq in 30 ml saline injected over 5 min) and a subsequent injection of 100 ml saline for rinsing of the syringe and the connecting hose, a swelling of the upper left arm was noted, and the patient confirmed a feeling of tenderness in the upper left arm. Extravasation was suspected and confirmed by whole-body scintigraphy as well as SPECT/CT of the left arm.

The whole-body scintigraphy was initiated 83 min after injection start and showed a large concentration of activity in the upper left arm, while there was only little

activity in the remainder of the body at this time point (Fig. 1). The SPECT/CT (started 110 min after injection start) showed activity in the subcutaneous tissue on both the medial and lateral side of the upper left arm (Fig. 2), and the later analysis of a quantitative SPECT reconstruction showed that more than half of the injected dose was located in the upper arm.

In order to stimulate the lymphatic drainage [2, 8], the patient was instructed to both elevate and exercise the affected arm by flexing the elbow, and a compression bandage with heated gel pads was applied to the relevant area. This stimulation was initiated shortly after confirmation of extravasation by the whole-body and SPECT/CT scans.

The standard protocol for nephroprotection with infusion of 25 g of lysine and 25 g of arginine dissolved in 1 l normal saline, and additionally 1 l of normal saline over 4 h was extended to 12 h with infusion of one additional solution of 25 g lysine and 25 g arginine in 1 l of saline. Finally, a separate infusion of 0.5 l saline with arginine and lysine over 2 h, 24 h after the treatment, was performed in order to extend the protection of the kidneys.

The day after the treatment (day 1), another whole-body scintigraphy and a quantitative SPECT/CT scan of the arm showed a dramatic decrease in total activity in the affected arm, and it was later estimated that less than 1% of the injected activity remained in the arm. The images showed high uptake in the metastasis in the liver and peritoneum correlating to the lesions of the pretherapeutic ^{68}Ga Ga-DOTATOC PET/CT and a normal physiological uptake in the spleen, liver, and bladder.

Whole-body scintigraphies performed 4 and 7 days after injection showed a further decrease of the activity in the arm relative to activity in the abdominal region, see Fig. 1. SPECT/CT scans of the abdomen were also

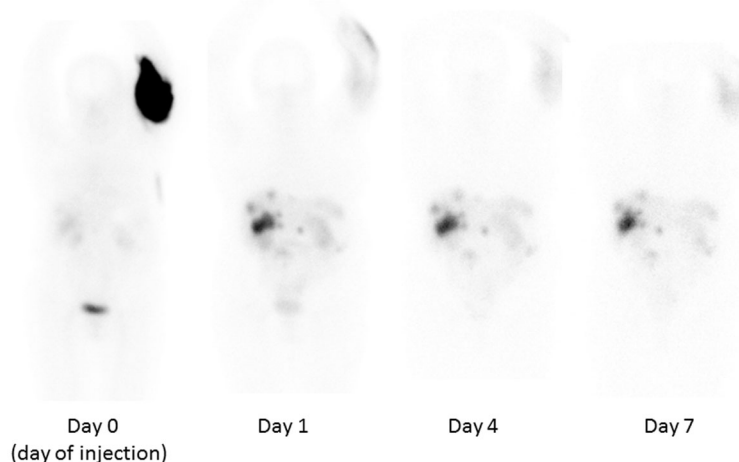
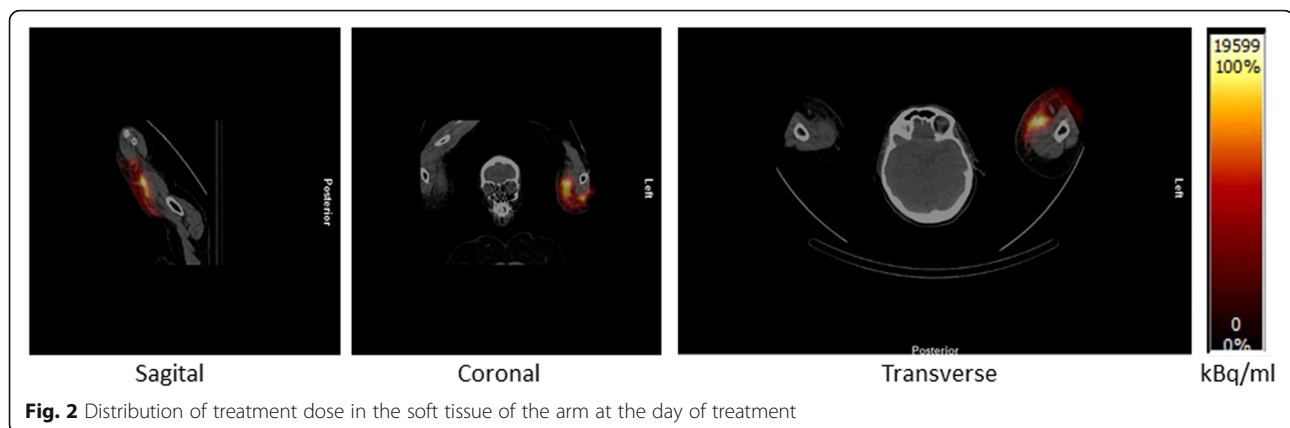


Fig. 1 Anterior views of whole-body scintigraphies performed at day 0, day 1, day 4 and day 7. The activity initially located in the arm is redistributed to organs and tumors in the abdominal region



performed at day 4 and day 7 for dosimetry of kidneys and tumors as described below.

The remaining activity in the arm was also assessed at different time points by measurement of the dose rate close to the skin surface of the affected upper arm using a Rados RDS-100 survey meter (Table 1). The temporal development of activity in the left arm, the abdominal-pelvic region, and the dose rate at contact with the arm is shown in Fig. 3, which indeed demonstrates a rapid decline of activity in the arm. The temporal development of the geometric mean over the arm and the dose rate is in very good agreement. In addition, delayed uptake of activity in the abdominal organs and tumors and the bladder can be observed.

The patient had no symptoms from the affected arm, or in general, and was discharged 2 days after the PRRT. The patient was contacted daily by the outpatient clinic in the week after the discharge, and the patient did not report any discomfort, which was also not the case during the 1-year follow-up. There were no complications in the following three treatment cycles, where PRRT was given in a central venous catheter.

Dosimetry

The SPECT/CT scans were recorded using a Siemens Symbia T16 SPECT/CT scanner (Siemens Medical Solutions USA, Inc.; 208 keV photopeak, medium energy collimator, 40 s/view (day 0 and day 1) or 60 s/view (day 4 and day 7), 32 views per detector, 128 × 128 matrix, 4.8 mm

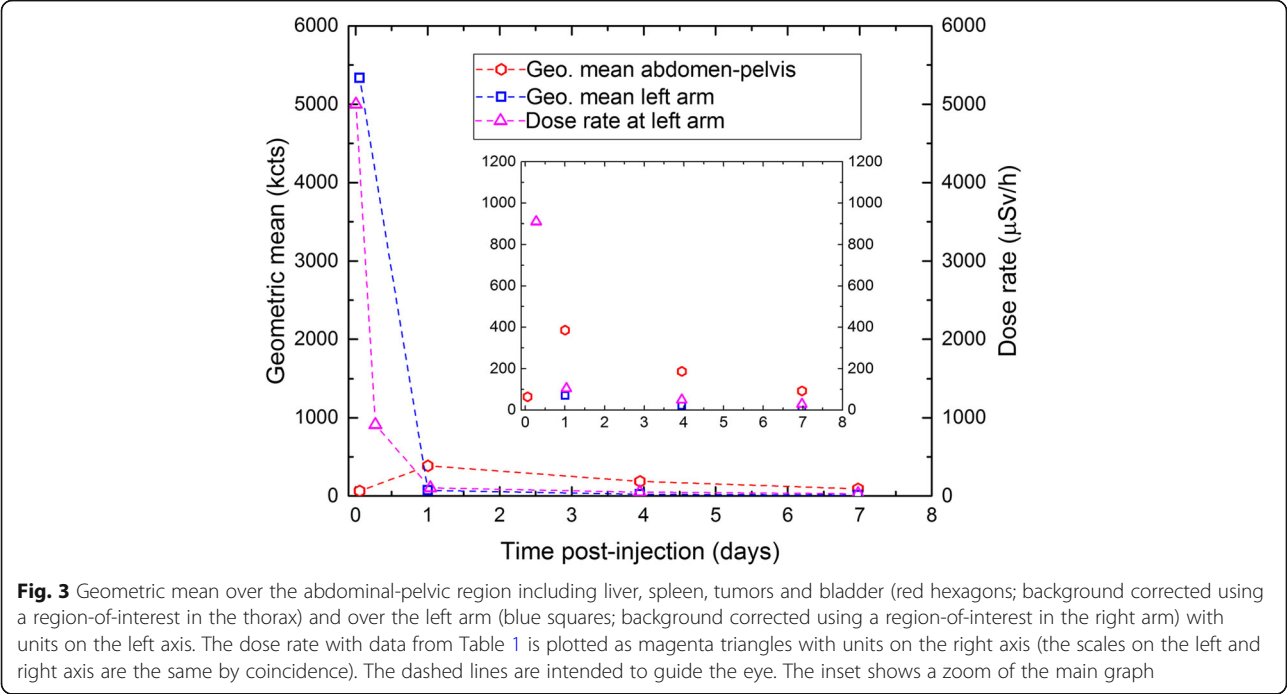
pixel size and CT with 110 kV and 60 mAs (quality ref.) and reconstructed as a quantitative SPECT/CT scan with prior calibration following Beauregard et al. [9]. For analysis of the radiation dose to the kidneys and selected tumors, the scans over the abdomen at days 1, 4, and 7 after injection were reconstructed with pixel values equal to activity concentration in units of 100 Bq/ml.

The kidneys were delineated manually in Hermes Hybrid Viewer (Hermes Medical Solutions AB, Sweden) on each CT scan; the volume was transferred to the corresponding quantitative SPECT reconstruction, and the mean concentration of ^{177}Lu in each kidney was determined. The mean concentration was converted to units of *kilobecquerel per milliliter* (kBq/ml) and plotted versus time post-injection (Fig. 4a). Normally, the data are fitted to a mono-exponential decay function, and the time-integrated activity concentration is determined as the area under this curve (AUC, area-under-curve). The absorbed dose is calculated by multiplying AUC with the three factors 1.95 mGy ml/(kBq d) (assuming total beta radiation absorption with mean beta energy 0.1479 MeV [10] in the kidney tissue with density 1.05 g/ml [11]), 1.05 (accounting for gamma radiation contributions [12]), and 1/0.85 (to account for partial volume effects of the delineated volume [13]). In the first treatment cycle of the present case, a mono-exponential decay fit would, however, lead to an overestimate of the dose as the uptake in the kidneys are delayed in comparison with an i.v. injection. Therefore, the initial uptake is approximated by a straight line from zero activity at injection to the first data point, and only after the first data point a mono-exponential decay function is applied (see Fig. 4a). The linear approximation results in a correction of -0.7 Gy for both kidneys as compared to a calculation where only a mono-exponential decay function is applied.

Two tumors in the liver with high uptake were delineated by setting a 50% threshold of the maximum concentration in each tumor as they were not distinguishable from normal liver tissue on the CT scan. The mean concentration

Table 1 Dose rate at contact with the injection site in the left arm

Time post-injection (hours)	Dose rate ($\mu\text{Sv/h}$)
0.1	5000
6.6	910
24.9	104
94.7	49
167.4	29



within the thresholded volumes at days 1, 4, and 7 was plotted against time post-injection and the AUC determined, again using a linear approximation until the first data point and a mono-exponential decay function thereafter (see Fig. 4b). The AUC was multiplied by the same factors as for the kidneys to derive a measure of the absorbed dose of the two tumors. The dose derived in this way is not necessarily equal to the mean dose of the tumor; it is a dose measure

which enables a comparison between the two treatment cycles. The absorbed dose, the specific dose, and the effective decay time of each kidney and tumor are given in Table 2.

Quantitative SPECT/CT scans at days 1, 4, and 7 after the second PRRT of the patient, 9 weeks after the initial treatment, were analyzed as above (without linear extrapolation to the first data point), and data are also shown in Fig. 4 and Table 2.

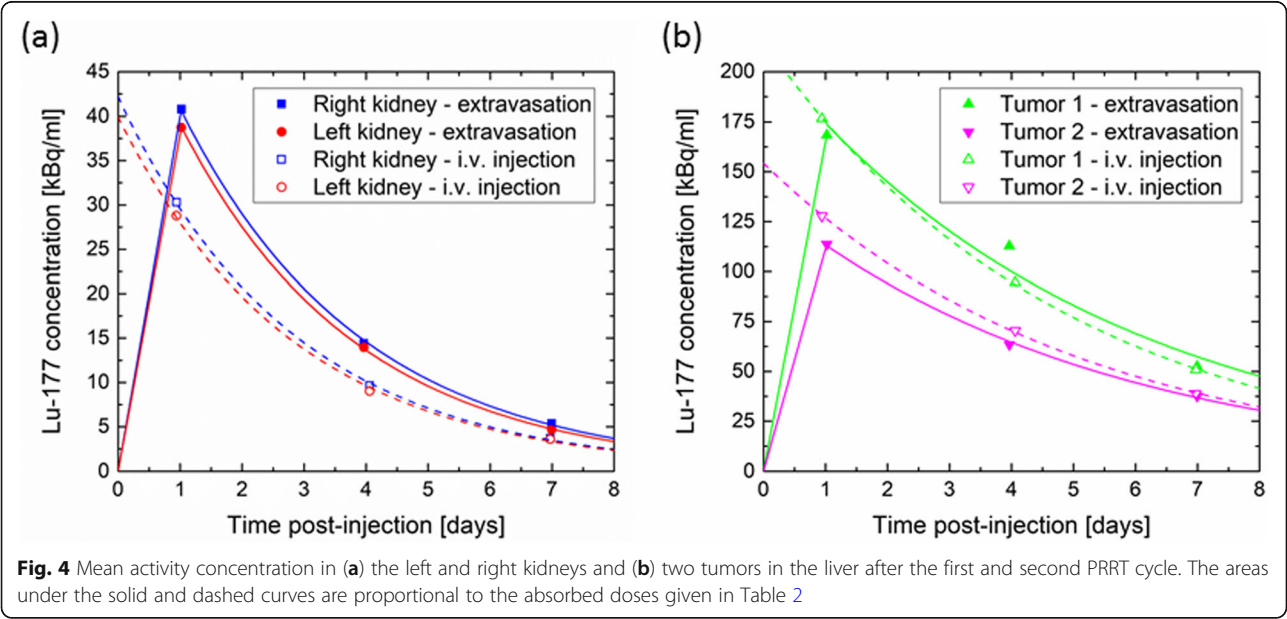


Table 2 Dosimetry of the left and right kidneys and two tumors in the liver

		First treatment (extravasation)	Second treatment (i.v. injection)
Right kidney	Activity (GBq)	7.5	7.6
	Absorbed dose (Gy)	3.3	2.9
	Specific dose (Gy/GBq)	0.45	0.37
	Effective half-life (days)	2.0	1.9
Left kidney	Absorbed dose (Gy)	3.1	2.7
	Specific dose (Gy/GBq)	0.42	0.36
	Effective half-life (days)	2.0	2.0
Tumor 1	Absorbed dose (Gy)	25	25
	Specific dose (Gy/GBq)	3.3	3.3
	Effective half-life (days)	3.7	3.4
Tumor 2	Absorbed dose (Gy)	16	19
	Specific dose (Gy/GBq)	2.1	2.5
	Effective half-life (days)	3.7	3.5

The doses to the kidneys and tumors are in very good agreement between the first and the second treatment taking into account the natural variation between treatments, the uncertainty of the dosimetry method, and in particular the uncertainty related to the linear approximation from injection to the first data point after the first treatment. This leads us to conclude that no change of the treatment course was necessary to compensate for a possibly incomplete treatment as a result of the extravasation. The third and the fourth treatments were carried out as planned. After these treatment cycles, only a single quantitative SPECT/CT scan was performed at day 1, and the same effective half-life as after the second treatment was assumed for kidney dosimetry. At the third treatment with 7.9 GBq [^{177}Lu]Lu-DOTATOC, the absorbed doses of both kidneys were 3.1 Gy, and at the fourth treatment with 8.0 GBq [^{177}Lu]Lu-DOTATOC, the absorbed doses of the right and left kidneys were 3.3 Gy and 3.1 Gy, respectively.

The absorbed dose to the skin epidermal basal layer near the injection site can be estimated as follows from the dose rate measurements and a quantitative SPECT/CT scan. By assuming that the temporal evolution of the activity near the injection site follows the dose rate measurements and scaling these data to the concentration found from a quantitative SPECT/CT scan of the arm, a time-activity curve can be generated and from this the AUC and the absorbed dose to the volume containing the extravasate be determined. The scaling factor is determined using the SPECT/CT scan at day 1, and the dose rate measurement at 24.9 h performed immediately before the scan. At this time point, the mean concentration in a volume defined by a 50% threshold of the local maximum was 163 kBq/ml (the volume is 14 ml), and hence, the scaling factor is 1.567 kBq h/(ml μSv). The

AUC is calculated using the trapezoidal rule between the data points and extrapolating to time zero and infinity by using the slope found from linear interpolation between the first two and the last two data points, respectively. By assuming total absorption of beta-radiation in tissue of density 1.0 g/ml, the AUC should be multiplied by 85.3 $\mu\text{Gy ml}/(\text{kBq h})$ to calculate the absorbed dose, which is then found to be 6 Gy. The dose to the epidermal basal layer is approximately half of this dose, i.e., 3 Gy, as the epidermal basal layer is only irradiated from one side [14].

Discussion

As already mentioned, only one of the cases of extravasation reported in the literature is concerned with a [^{177}Lu]Lu-labelled peptide. Tyłski and colleagues [3] described a case with [^{177}Lu]Lu-DOTATATE, where they found a quick elimination of the drug from the arm with an effective half-life of 3 h and that the elimination could be increased by local warming and repeated massage of the injection site. This patient was also without any clinical signs of radiation damage.

A similar case with [^{90}Y]Y-DOTATOC was reported by Terwinghe et al. [8]. They also found a remarkable decrease in activity in the arm, which at first contained all of the injected 3.5 GBq [^{90}Y]Y-DOTATOC. The dose rate at contact with the arm fell from 75 to 1 mSv/h in a day, and Bremsstrahlung images showed significantly lower retention of [^{90}Y]Y-DOTATOC the day after treatment, with a decrease of 91% from the day of treatment. Terwinghe et al. concluded at that time, in 2012, that the relatively small molecule [^{90}Y]Y-DOTATOC (molar mass 1.5 kDa) has a lower retention in subcutaneous tissue than heavier molecules like the monoclonal antibody [^{90}Y]Y-Ibritumomab tiuxetan (Zevalin, used for

treatment of non-Hodgkin's lymphoma, molar mass about 148 kDa) as there had been reports of pronounced local radiation damage and skin necrosis after extravasation with [^{90}Y]Y-Ibritumomab tiuxetan [15, 16].

In contrast to the conclusion of Terwinghe et al., a case of extravasation with the relatively large [^{177}Lu]Lu-PSMA molecule (molar mass about 84 kDa) was reported by Schlenkhoff and colleagues in 2017 [4], where no symptoms from the arm and no complications afterwards were observed. The case was very similar to the present one, but they took a different approach to treatment with attempts to squeeze the fluid back via the catheter, followed by heating of the injection area for 12 h, and finally by cooling the area and no movement of the affected arm. They also found a rapid decline of activity in the arm and a normal distribution of [^{177}Lu]Lu-PSMA after 20 h. Furthermore, the reports of skin burns [14] and development of subcutaneous squamous carcinoma [5] after extravasation with the small molecules [^{131}I]I-metaiodobenzylguanidine (MIBG, 0.3 kDa) and $^{223}\text{RaCl}_2$ (Xofigo, 0.3 kDa), respectively, are also in contrast to the conclusion of Terwinghe et al.

The lack of complications after extravasation of [^{177}Lu]Lu-PSMA and the serious complications observed after extravasation of [^{131}I]I-MIBG and $^{223}\text{RaCl}_2$ are inconsistent with the hypothesis that extravasation of small molecules should result in little radiation damage of the skin due to a lower retention in subcutaneous tissue. Instead, we note that in the above-mentioned cases [3, 4, 8], as well as the present case, where no complications were observed, there was an immediate treatment by local heating, massage, or exercise, as recommended both in the EANM procedure guidelines for treatment with [^{90}Y]Y-Ibritumomab tiuxetan (Zevalin®) [17] and $^{223}\text{RaCl}_2$ (Xofigo®) [18] and in the product characteristics of Lutathera® ([^{177}Lu]Lu-DOTATATE) [19]. In most of the reported cases with serious radiation damage [5, 14, 15, 16], no immediate treatment was initiated, while in one recent case with [^{90}Y]Y-Ibritumomab tiuxetan [6], a patient was in need for surgery with removal of necrotic skin and soft tissue even though extravasation was quickly realized and early treatment was attempted by aspiration of the puncture site and massage of the arm. These observations from cases with and without radiation damage indicate that immediate and efficient treatment is decisive for the outcome after extravasation regardless of the size of the molecule.

It is also noteworthy that in the cases without tissue damage [3, 4, 8], relatively large volumes of saline was co-infused with the therapeutic drug leading to a somewhat lower radioactivity concentration than in cases with tissue damage. In particular, the infusion of 1.2 GBq of ^{90}Y in 10 ml in Zevalin treatments results in a relatively high concentration of the high-energy beta-

emitter ^{90}Y and hence a relatively high absorbed dose near the injection site in the arm.

In the present case, we found that after immediate initiation of massage, heating, and exercise of the arm, the radio-therapeutic drug was redistributed to the organs and tumors as we would expect after a successful i.v. injection. The successful treatment of the extravasation could easily be verified as a drop in dose rate measured by using a survey meter. The absorbed dose to the epidermal basal layer was estimated to 3 Gy. At this dose, no damage to the skin is anticipated according to [3], where a dose of 2.8–7.8 Gy was estimated and no clinical signs of irradiation were found, and according to Fig. 1 in [6] where the mildest clinical response shown, a transient depilation, occurs at a dose of 4–6 Gy. In other cases where higher absorbed doses of 10–20 Gy (acute) plus 12–16 Gy (low dose rate irradiation) [14], 20–40 Gy [16] and 43 Gy [6] have been estimated, a moist or wet desquamation, or even skin necrosis was observed.

Further, in the present case, dosimetry of the kidneys and tumors after the first and the second PRRT cycle documented that even after extravasation the absorbed doses to the tumors were similar to those after a successful injection, and therefore, no additional PRRT cycle was scheduled for the patient after the extravasation.

As a growing amount of therapeutic injections in nuclear medicine are being performed, there is an increasing need for guidelines regarding extravasation both with respect to prevention and to early and delayed treatment. As a consequence of the present case, we have adapted some of the advices mentioned by Williams and coworkers [16] in an institutional guideline for our different radionuclide therapies. In order to prevent further incidents, we have clarified our procedures for intravenous therapy so that the needle is now being placed in the upper third of the lower arm, avoiding the joint area, and ultrasound is being used in difficult cases. In patients with a known history of difficult intravenous access, a central venous catheter is used for the therapy. The use of a new venipuncture site in large veins, including central venous catheter, and checking for blood return was already incorporated in our procedures. Regarding the early treatment of extravasation, we recommend massage, heating, exercise and elevation, and monitoring by a survey meter as mentioned above. With appropriate measurements, it is feasible to estimate radiation dose to the epidermal basal layer and hence the severity of the extravasation and ultimately the prognosis.

Abbreviations

AUC: Area-under-curve; CT: Computed tomography; DOTATATE: (Dota⁰-Tyr³)octreotate; DOTATOC: (Dota⁰-Phe¹-Tyr³)octreotide; LAR: Octreotide long-acting repeatable; MIBG: Metaiodobenzylguanidine; NET: Neuroendocrine tumor; PRRT: Peptide-receptor radionuclide therapy; PSMA: Prostate-specific membrane antigen; SPECT: Single-photon emission computed tomography

Acknowledgements

Not applicable

Authors' contributions

AKA, ACB, and HB decided on and were responsible for the treatment of extravasation; GEV was responsible at the gastroenterology ward and for patient follow-up; ACB performed the measurement and scans which was interpreted and analyzed by AKA and PFS, and PI was the treating physician at treatment cycles 2–4. The manuscript was drafted by AKA and PFS and edited by all authors. All authors have read and approved the final manuscript.

Funding

None

Availability of data and materials

The datasets used or analyzed during the current study are available from the corresponding author on reasonable request.

Ethics approval and consent to participate

The requirement for ethics approval was waived by The Central Denmark Region Committees on Health Research Ethics.

Consent for publication

The patient provided written informed consent to publication of this report.

Competing interests

The authors declare that they have no competing interests.

Author details

¹Department of Nuclear Medicine and PET-Centre, Aarhus University Hospital, Palle Juul-Jensens Boulevard 165, 8200 Aarhus N, Denmark. ²Department of Hepatology and Gastroenterology, Aarhus University Hospital, Palle Juul-Jensens Boulevard 99, 8200 Aarhus N, Denmark.

Received: 15 April 2020 Accepted: 9 June 2020

Published online: 23 June 2020

References

- Strosberg J, El-Haddad G, Wolin E, Hendifar A, Yao J, Chasen B, et al. Phase 3 trial of ¹⁷⁷Lu-Dotatate for midgut neuroendocrine tumors. *N Engl J Med*. 2017;376:125–35.
- van der Pol J, Vöö S, Bucerius J, Mottaghy FM. Consequences of radiopharmaceutical extravasation and therapeutic interventions: a systematic review. *Eur J Nucl Med Mol Imaging*. 2017;44:1234–43.
- Tylski P, Vuillod A, Goutain-Majorel C, Jalade P. Dose estimation for an extravasation in a patient treated with ¹⁷⁷Lu-DOTATATE. *Physica Medica*. 2018;56:32–3.
- Schlenkhoff CD, Essler M, Ahmadzadehfar H. Possible treatment approach to an extravasation of ¹⁷⁷Lu-PSMA-617. *Clin Nucl Med*. 2017;42:639–40.
- Benjergdes KE, Brown SC, Housewright CD. Focal cutaneous squamous cell carcinoma following radium-223 extravasation. *Proc (Baylor Univ Med Cent)*. 2017;30(1):78–9.
- Baus A, Keilani C, Bich C-S, Entine F, Brachet M, Duhamel P, et al. Complex upper arm reconstruction using an antero-lateral thigh free flap after an extravasation of Yttrium-90-ibritumomab Tiuxetan; a case report and literature review. *Ann Chir Plast Esthet*. 2018;63:175–81.
- Bodei L, Mueller-Brand J, Baum RP, Pavel ME, Hörsch D, O'Dorisio MS, et al. The joint IAEA, EANM, and SNMMI practical guidance on peptide receptor radionuclide therapy (PRRT) in neuroendocrine tumours. *Eur J Nucl Med Mol Imaging*. 2013;40:800–16.
- Terwinghe C, Vanbilloen B, Van Binnebeek S, Baete K, Bergans N, Koole M, et al. Extravasation of ⁹⁰Y-DOTATOC: case report and discussion of potential effects, remedies and precautions in PRRT. *Eur J Nucl Med Mol Imaging*. 2012;39(OP267):S155–303.
- Beauregard J-M, Hofman MS, Pereira JM, Eu P, Hicks RJ. Quantitative ¹⁷⁷Lu SPECT (QSPECT) imaging using a commercially available SPECT/CT system. *Cancer Imaging*. 2011;11:56–66.
- Eckerman K, Endo A. ICRP Publication 107. Nuclear decay data for dosimetric calculations. *Ann ICRP*. 2008;38:7–96.
- Valentin J. Basic anatomical and physiological data for use in radiological protection: reference values: ICRP Publication 89. *Ann ICRP*. 2002;32:1–277.
- Hippeläinen ET, Tenhunen MJ, Mäenpää HO, Heikkonen JJ, Sohlberg AO. Dosimetry software Hermes Internal Radiation dosimetry: from quantitative image reconstruction to voxel-level absorbed dose distribution. *Nucl Med Commun*. 2017;38:357–65.
- Ljungberg M, Celler A, Konijnenberg MW, Eckerman KF, Dewaraja YK, Sjögreen-Gleisner K. MIRD pamphlet no. 26: joint EANM/MIRD guidelines for quantitative ¹⁷⁷Lu SPECT applied for dosimetry of radiopharmaceutical therapy. *J Nucl Med*. 2016;57:151–62.
- Bonta DV, Halkar RK, Alazraki N. Extravasation of a therapeutic dose of ¹³¹I-metaiodobenzylguanidine: prevention, dosimetry, and mitigation. *J Nucl Med*. 2011;52:1418–22.
- Siebeneck BM. Extravasation of yttrium-90 ibritumomab tiuxetan: a case study. *Clin J Oncol Nurs*. 2008;12:275–8.
- Williams G, Palmer MR, Parker JA, Joyce R. Extravasation of Therapeutic Yttrium-90- Ibritumomab Tiuxetan (Zevalin®): A Case Report. *Cancer Biother Radiopharm*. 2006; 21:101–5.
- Tennvall J, Fischer M, Delaloye AB, Bombardieri E, Bodei L, Giammarile F, et al. EANM procedure guideline of radio-immunotherapy for B-cell lymphoma with ⁹⁰Y-radiolabelled ibritumomab tiuxetan (Zevalin). *Eur J Nucl Med Mol Imaging*. 2007;34:616–22.
- Poeppel TD, Handkiewicz-Junak D, Andreoff M, Becherer A, Bockisch A, Fricke E, et al. EANM guideline for radionuclide therapy with radium-223 of metastatic castration-resistant prostate cancer. *Eur J Nucl Med Mol Imaging*. 2018;45:824–45.
- Summary of Product Characteristics for Lutathera. https://www.ema.europa.eu/en/documents/product-information/lutathera-epar-product-information_en.pdf.

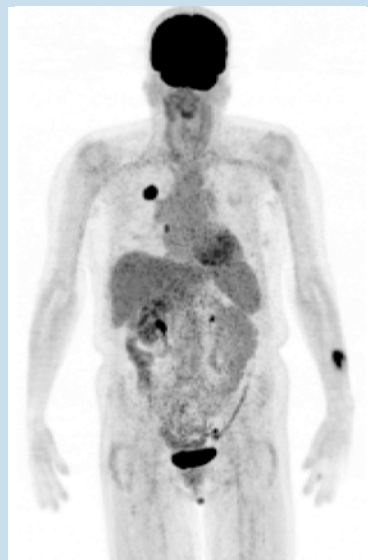
Publisher's Note

Springer Nature remains neutral with regard to jurisdictional claims in published maps and institutional affiliations.

Submit your manuscript to a SpringerOpen[®] journal and benefit from:

- Convenient online submission
- Rigorous peer review
- Open access: articles freely available online
- High visibility within the field
- Retaining the copyright to your article

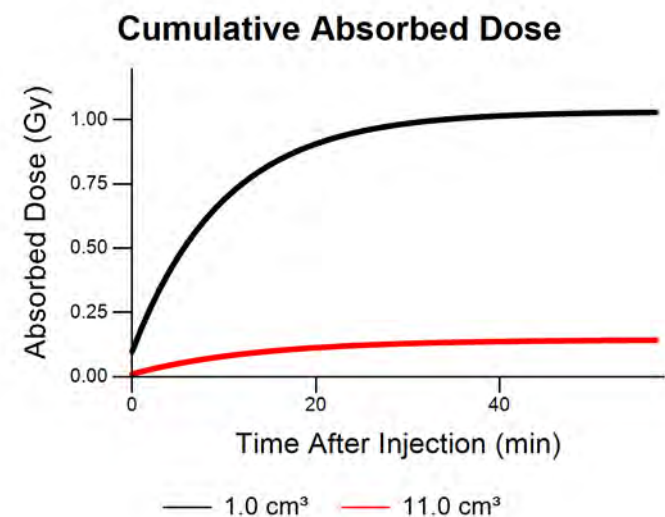
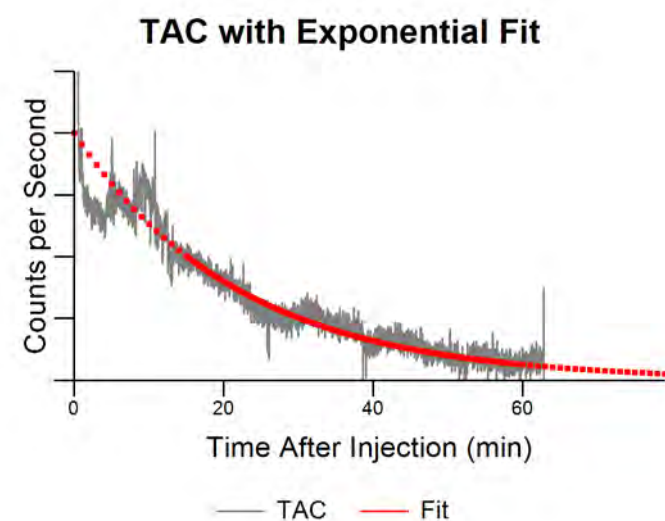
Submit your next manuscript at ► [springeropen.com](https://www.springeropen.com)

Scan #1499**Absorbed Dose: 0.1 to 1.0 Gy**

Isotope	F-18
Injection Method	Manual, IV
Injection Location	L Forearm
Injected Activity	17.67 mCi
Radiotracer Volume	1.50 mL
Saline Flush Volume	10.0 mL
Imaging Time	67.8 min
% Extravasation	7 %
Initial Activity	1.17 mCi
Imaging Time Activity	0.03 mCi
Reabsorption Rate	15.1 min
Dose Calculation Volume	1.00 to 11.00 cm ³
Dose Rate	84.4 to 8.7 mGy/mCi-min
Total Absorbed Dose	1.0 to 0.1 Gy

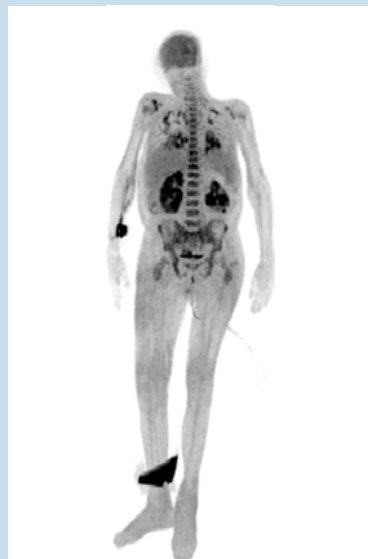
As part of their PET/CT imaging study, this patient was injected with 17.67 mCi of 18F-FDG. Based on PET images and Lara time-activity data, we estimate that approximately 6.6% of the injected radioactivity was infiltrated into the left forearm.

Absorbed dose to the tissue was estimated to be between 0.14 Gy and 1.03 Gy.



Scan #12052

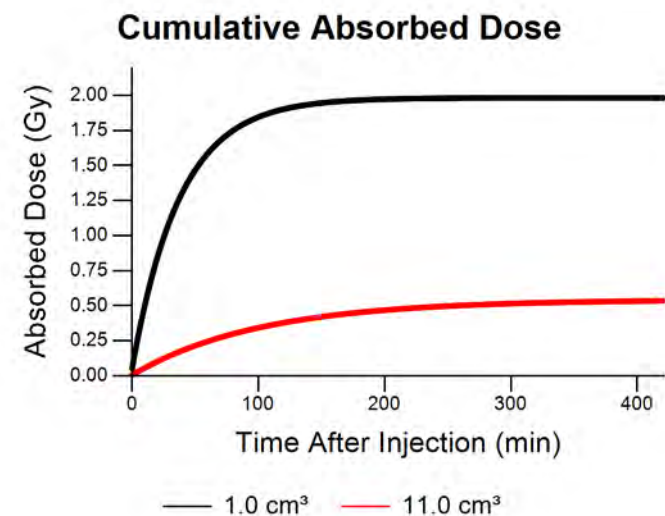
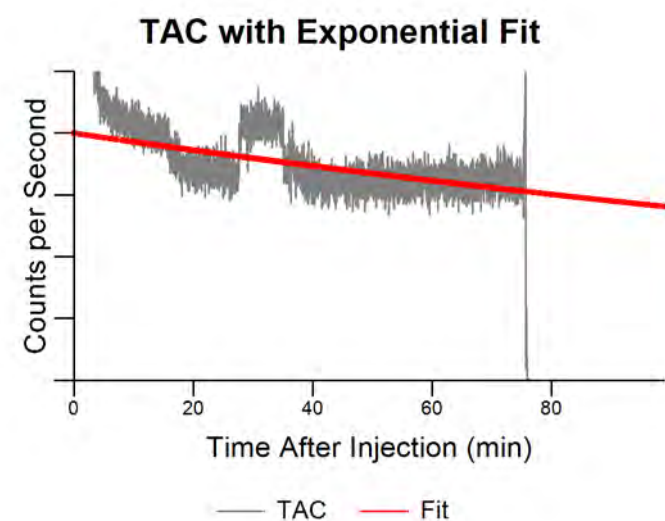
Absorbed Dose: 0.5 to 2.0 Gy

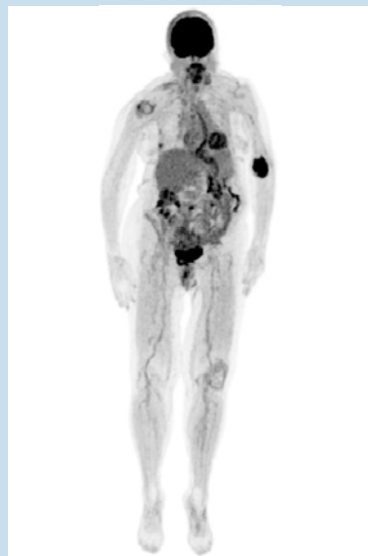


Isotope	F-18
Injection Method	Manual, IV
Injection Location	R Forearm
Injected Activity	10.60 mCi
Radiotracer Volume	1.50 mL
Saline Flush Volume	10.0 mL
Imaging Time	60.0 min
% Extravasation	6 %
Initial Activity	0.61 mCi
Imaging Time Activity	0.34 mCi
Reabsorption Rate	195.1 min
Dose Calculation Volume	1.00 to 11.00 cm ³
Dose Rate	84.4 to 8.7 mGy/mCi-min
Total Absorbed Dose	2.0 to 0.5 Gy

As part of an 18F-FDG PET scan, the patient was injected with 10.6 mCi followed by a saline flush of 10 mL. PET imaging and Lara time-activity data indicated that approximately 5.8% of the injected activity was infiltrated into the patient's right forearm.

We estimate that the arm tissue was subjected to between 0.53 Gy and 1.98 Gy of unintended dose.

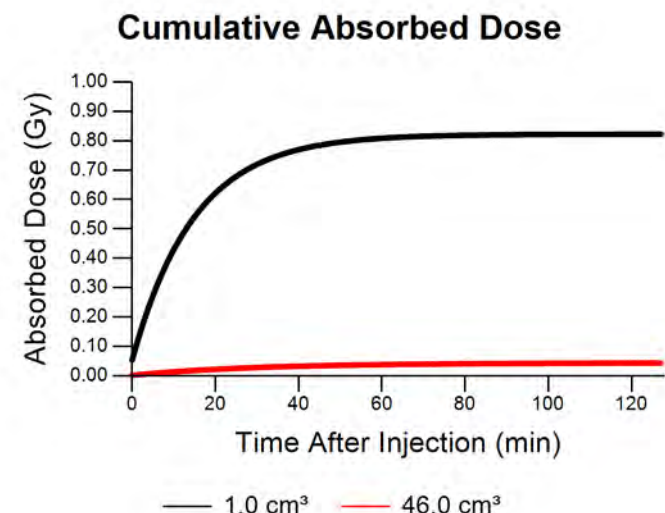
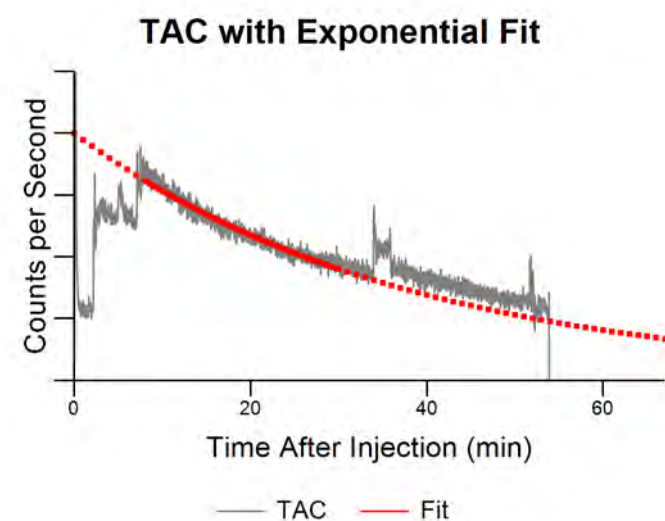


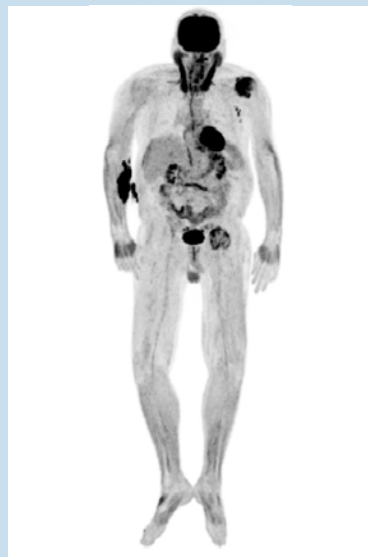Scan #13365**Absorbed Dose: 0.0 to 0.8 Gy**

Isotope	F-18
Injection Method	Autoinjector, IV
Injection Location	L Antecubital
Injected Activity	9.95 mCi
Radiotracer Volume	1.50 mL
Saline Flush Volume	45.0 mL
Imaging Time	60.0 min
% Extravasation	6 %
Initial Activity	0.63 mCi
Imaging Time Activity	0.09 mCi
Reabsorption Rate	26.1 min
Dose Calculation Volume	1.00 to 46.00 cm ³
Dose Rate	84.4 to 2.2 mGy/mCi-min
Total Absorbed Dose	0.8 to 0.0 Gy

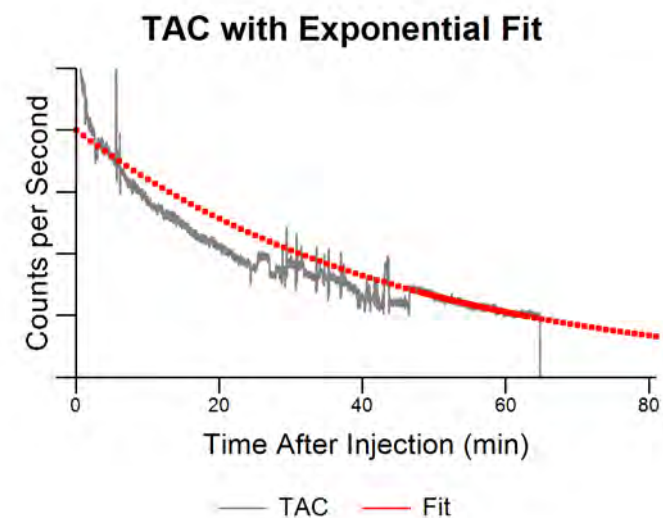
For an 18F-FDG PET scan, the patient was injected with 9.95 mCi followed by a saline flush of 45 mL. PET imaging and Lara time-activity data indicated that approximately 6.4% of the injected activity was infiltrated into the patient's left antecubital fossa.

We estimate that the arm tissue was subjected to between 0.04 Gy and 0.82 Gy of unintended dose.



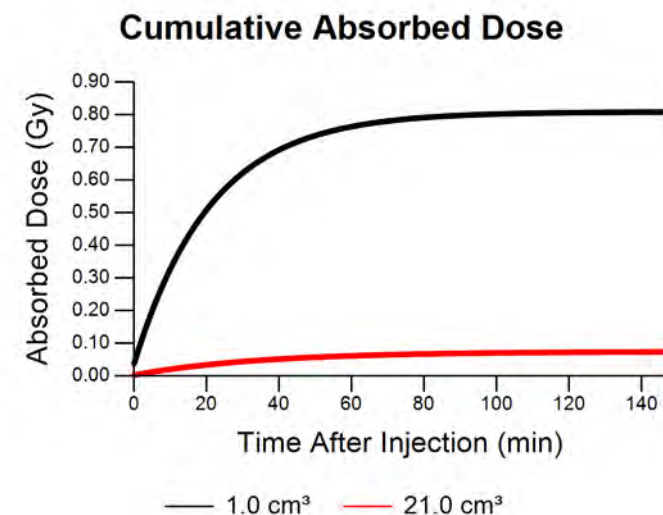
Scan #14338**Absorbed Dose: 0.1 to 0.8 Gy**

Isotope	F-18
Injection Method	Manual, IV
Injection Location	R Forearm
Injected Activity	10.56 mCi
Radiotracer Volume	1.50 mL
Saline Flush Volume	20.0 mL
Imaging Time	60.0 min
% Extravasation	4 %
Initial Activity	0.44 mCi
Imaging Time Activity	0.08 mCi
Reabsorption Rate	31.3 min
Dose Calculation Volume	1.00 to 21.00 cm ³
Dose Rate	84.4 to 4.7 mGy/mCi-min
Total Absorbed Dose	0.8 to 0.1 Gy

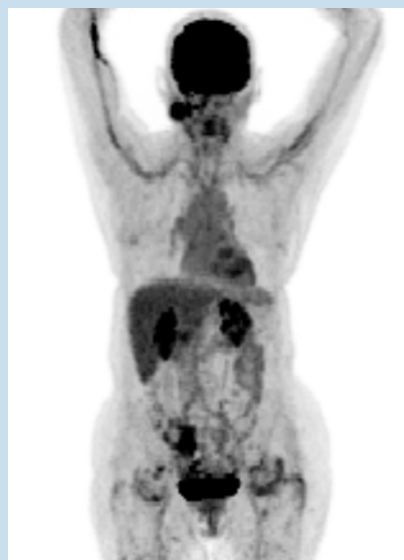

For an 18F-FDG PET scan, the patient was injected with 10.56 mCi followed by a saline flush of 20 mL. PET imaging and Lara time-activity data indicated that approximately 4.2% of the injected activity was infiltrated into the patient's right forearm.

We estimate that the arm tissue was subjected to between 0.07 Gy and 0.81 Gy of unintended dose.



Scan #15512

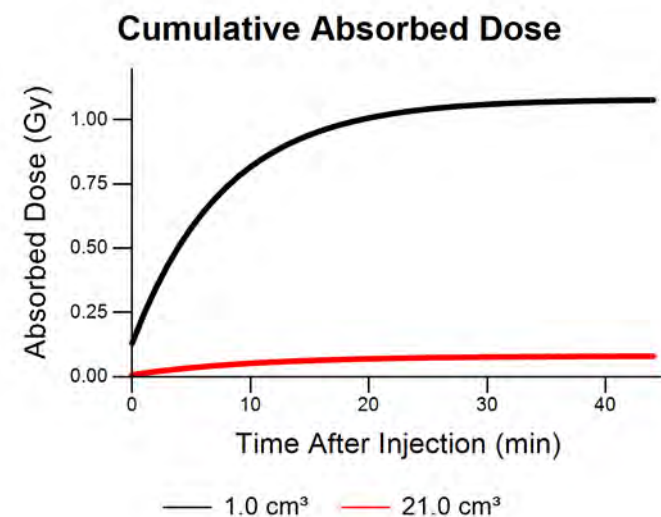
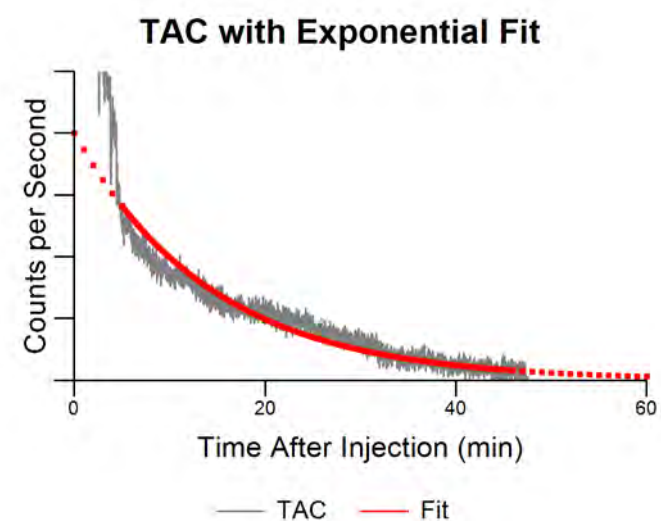


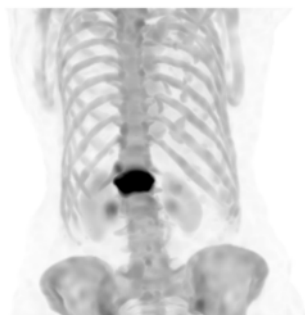Isotope	F-18
Injection Method	Manual, IV
Injection Location	R Antecubital
Injected Activity	10.64 mCi
Radiotracer Volume	1.50 mL
Saline Flush Volume	20.0 mL
Imaging Time	60.0 min
% Extravasation	14 %
Initial Activity	1.54 mCi
Imaging Time Activity	0.02 mCi
Reabsorption Rate	9.9 min
Dose Calculation Volume	1.00 to 21.00 cm ³
Dose Rate	84.4 to 4.7 mGy/mCi-min
Total Absorbed Dose	1.1 to 0.1 Gy

For an 18F-FDG PET scan, the patient was injected with 10.64 mCi followed by a saline flush of 20 mL. PET imaging and Lara time-activity data indicated that approximately 14.5% of the injected activity was infiltrated into the patient's right antecubital fossa.

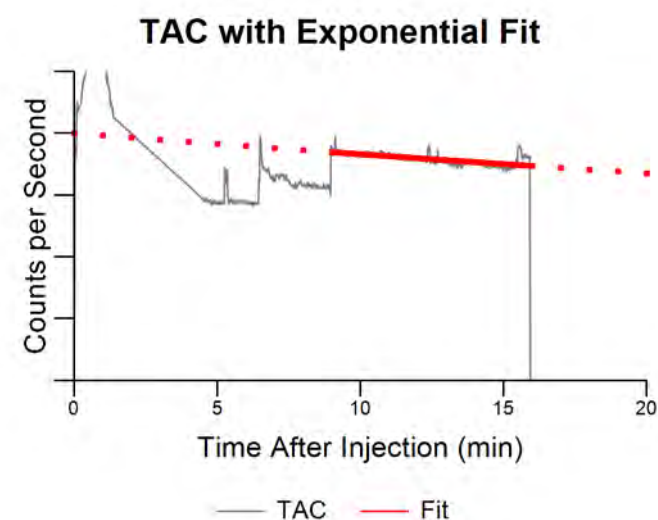
We estimate that the arm tissue was subjected to between 0.08 Gy and 1.08 Gy of unintended dose.

Absorbed Dose: 0.1 to 1.1 Gy



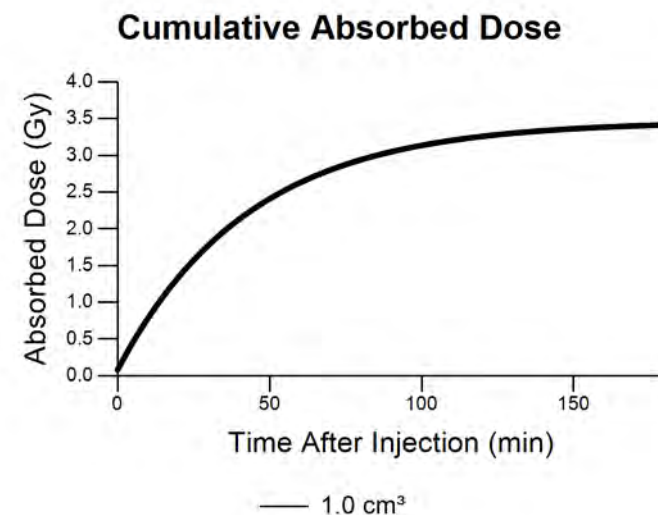
Scan #16524**Absorbed Dose: 3.5 Gy**

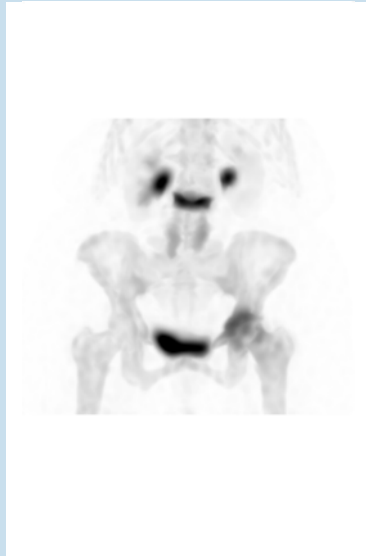Isotope	Tc-99m
Injection Method	Manual, Straight Stick
Injection Location	R Hand
Injected Activity	25.60 mCi
Radiotracer Volume	1.00 mL
Saline Flush Volume	0.0 mL
Imaging Time	240.0 min
% Extravasation	50 %
Initial Activity	12.80 mCi
Imaging Time Activity	0.96 mCi
Reabsorption Rate	78.1 min
Dose Calculation Volume	1.00 cm ³
Dose Rate	6.2 mGy/mCi-min
Total Absorbed Dose	3.5 Gy



This patient was injected with 25.6 mCi of Tc99m-MDP for a bone scan. The nuclear medicine technologist noted that the injection was difficult and that the patient was on blood thinners. They started by injecting into the left wrist, but could tell that the vein blew. They then switched to the right hand and continued the injection. They estimated that half of the injected volume was infiltrated.

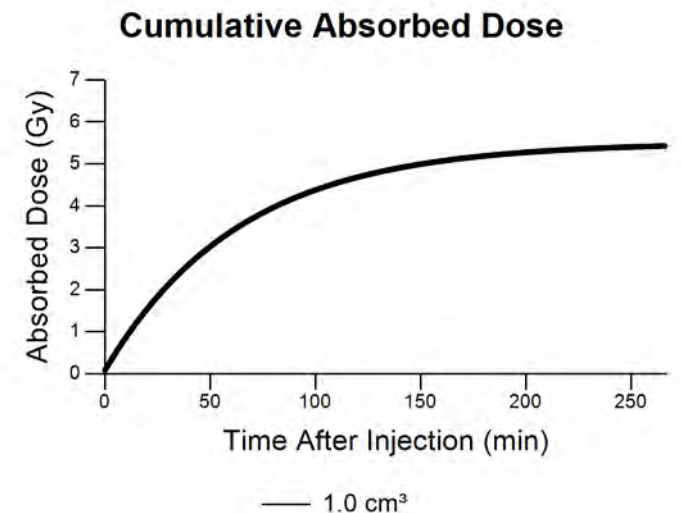
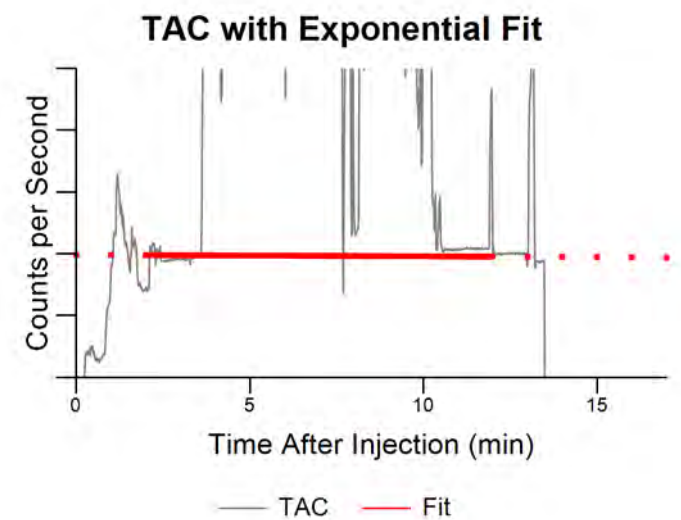
The SPECT image data was not quantifiable, but we calculated tissue dose assuming infiltration of 50% of injected activity. Lara sensor count rate data indicated biological clearance with a half-time of 78 minutes. For a tissue volume of 1 cm³, absorbed dose was calculated to be 3.47 Gy.

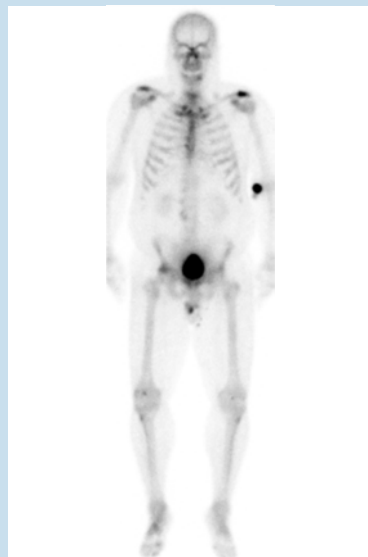

Scan #16846**Absorbed Dose: 5.5 Gy**

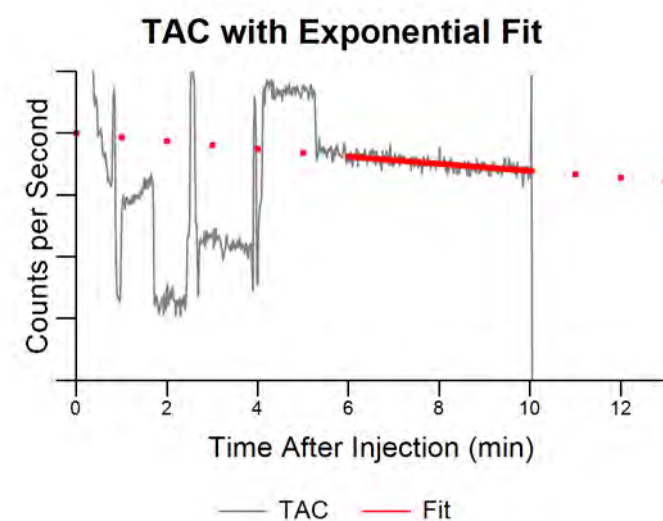
Isotope	Tc-99m
Injection Method	Manual, Straight Stick
Injection Location	R Antecubital
Injected Activity	27.50 mCi
Radiotracer Volume	1.00 mL
Saline Flush Volume	0.0 mL
Imaging Time	240.0 min
% Extravasation	50 %
Initial Activity	13.74 mCi
Imaging Time Activity	6.41 mCi
Reabsorption Rate	552.3 min
Dose Calculation Volume	1.00 cm ³
Dose Rate	6.2 mGy/mCi-min
Total Absorbed Dose	5.5 Gy

This patient was injected with 27.5 mCi of Tc99m-MDP for a bone scan. The SPECT image data was not quantifiable, but we calculated tissue dose assuming infiltration of 50% of injected activity. Lara sensor count rate data indicated biological clearance with a half-time of 9.2 hours (corrected for physical decay). For a tissue volume of 1 cm³, absorbed dose was calculated to be 5.51 Gy.

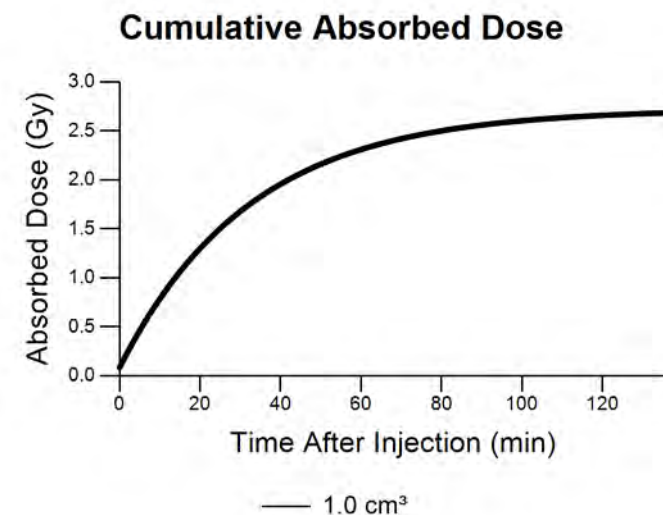


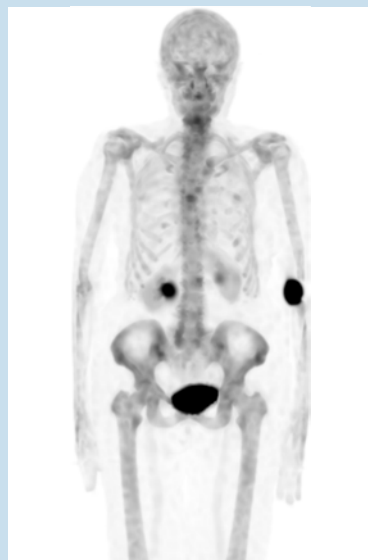Scan #17175**Absorbed Dose: 2.7 Gy**

Isotope	Tc-99m
Injection Method	Manual, Straight Stick
Injection Location	R Antecubital
Injected Activity	26.60 mCi
Radiotracer Volume	1.00 mL
Saline Flush Volume	0.0 mL
Imaging Time	240.0 min
% Extravasation	50 %
Initial Activity	13.30 mCi
Imaging Time Activity	0.16 mCi
Reabsorption Rate	42.0 min
Dose Calculation Volume	1.00 cm ³
Dose Rate	6.2 mGy/mCi-min
Total Absorbed Dose	2.7 Gy



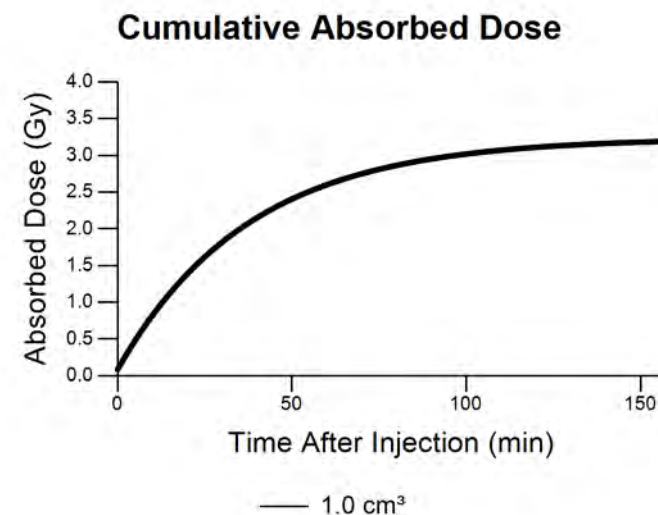
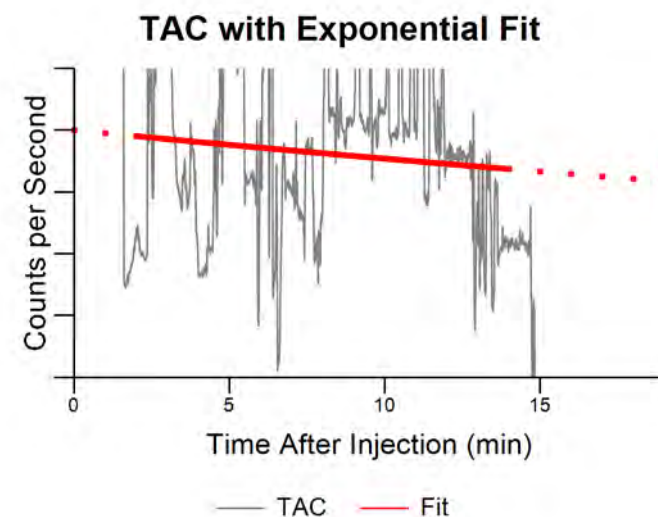
This patient was injected with 26.6 mCi of Tc99m-MDP for a bone scan. The SPECT image data was not quantifiable, but we calculated tissue dose assuming infiltration of 50% of injected activity. Lara sensor count rate data indicated biological clearance with a half-time of 42 minutes. For a tissue volume of 1 cm³, absorbed dose was calculated to be 2.72 Gy.

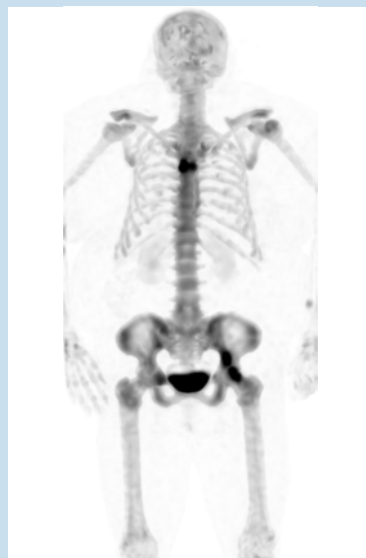

Scan #17202

Isotope	Tc-99m
Injection Method	Manual, Straight Stick
Injection Location	L Antecubital
Injected Activity	27.30 mCi
Radiotracer Volume	1.00 mL
Saline Flush Volume	0.0 mL
Imaging Time	240.0 min
% Extravasation	50 %
Initial Activity	13.66 mCi
Imaging Time Activity	0.46 mCi
Reabsorption Rate	56.8 min
Dose Calculation Volume	1.00 cm ³
Dose Rate	6.2 mGy/mCi-min
Total Absorbed Dose	3.2 Gy

This patient was injected with 27.3 mCi of Tc99m-MDP for a bone scan. The SPECT image data was not quantifiable, but we calculated tissue dose assuming infiltration of 50% of injected activity. Lara sensor count rate data indicated biological clearance with a half-time of 56.8 minutes. For a tissue volume of 1 cm³, absorbed dose was calculated to be 3.24 Gy.

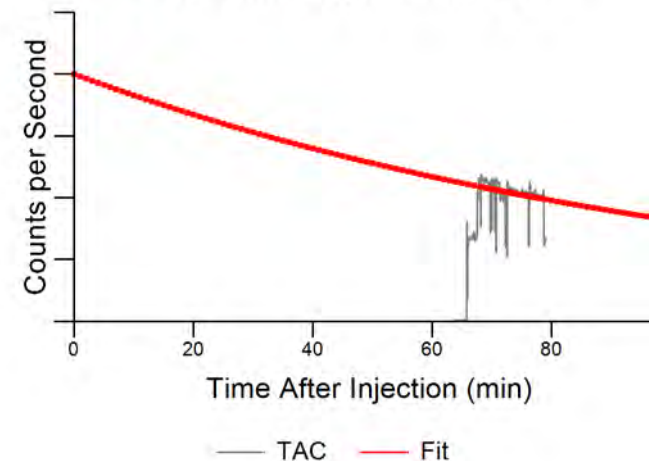
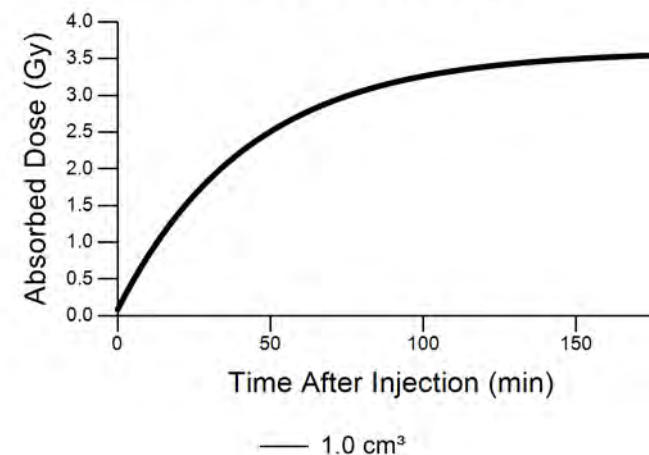
Absorbed Dose: 3.2 Gy

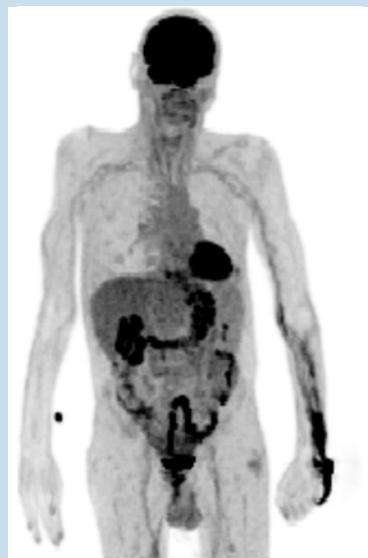Scan #17220**Absorbed Dose: 3.6 Gy**

Isotope	Tc-99m
Injection Method	Manual, IV
Injection Location	R Antecubital
Injected Activity	26.70 mCi
Radiotracer Volume	1.00 mL
Saline Flush Volume	0.0 mL
Imaging Time	240.0 min
% Extravasation	50 %
Initial Activity	13.34 mCi
Imaging Time Activity	0.99 mCi
Reabsorption Rate	77.6 min
Dose Calculation Volume	1.00 cm ³
Dose Rate	6.2 mGy/mCi-min
Total Absorbed Dose	3.6 Gy

This patient was injected with 26.7 mCi of Tc99m-MDP in the right antecubital fossa (not imaged) for a bone scan. The Lara injection monitor system was not used, but the technologist suspected infiltration of the injection. Sixty-four minutes after injection, the patient was able to return to the nuclear medicine department and the Lara sensors were placed onto their arms. The count rate data from this time was used to calculate a clearance rate.

We calculated tissue dose assuming infiltration of 50% of injected activity. Lara sensor count rate data indicated biological clearance with a half-time of 77.6 minutes. For a tissue volume of 1 cm³, absorbed dose was calculated to be 3.6 Gy.

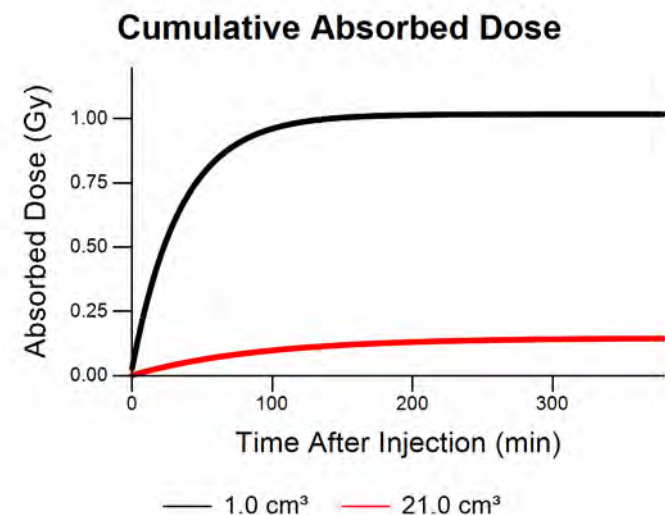
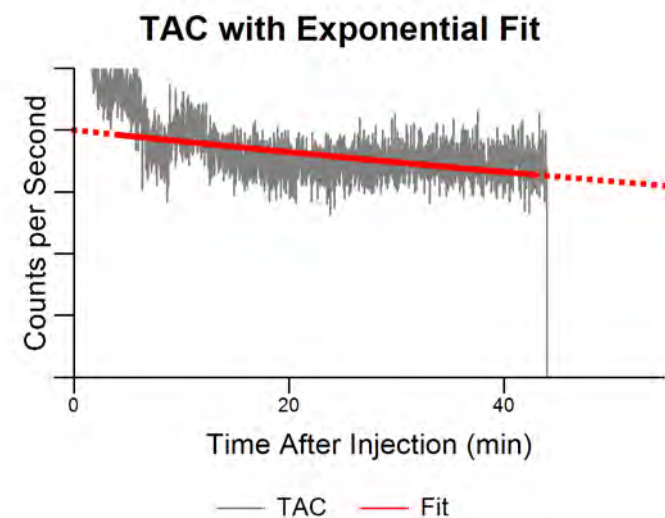
TAC with Exponential Fit**Cumulative Absorbed Dose**

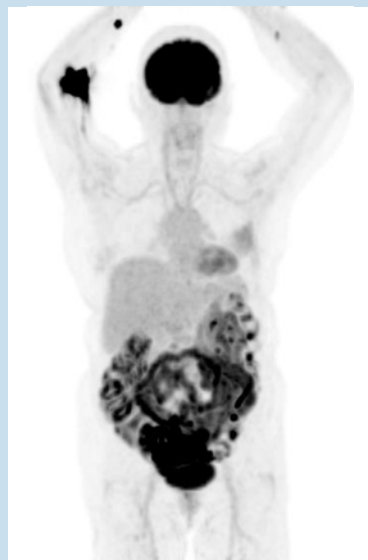Scan #17514

Isotope	F-18
Injection Method	Manual, IV
Injection Location	L Hand
Injected Activity	11.13 mCi
Radiotracer Volume	1.50 mL
Saline Flush Volume	20.0 mL
Imaging Time	60.0 min
% Extravasation	3 %
Initial Activity	0.34 mCi
Imaging Time Activity	0.18 mCi
Reabsorption Rate	149.9 min
Dose Calculation Volume	1.00 to 21.00 cm ³
Dose Rate	84.4 to 4.7 mGy/mCi-min
Total Absorbed Dose	1.0 to 0.1 Gy

For an 18F-FDG PET scan, the patient was injected with 11.13 mCi followed by a saline flush of 20 mL. PET imaging and Lara time-activity data indicated that approximately 3.1% of the injected activity was infiltrated into the patient's left hand.

We estimate that the arm tissue was subjected to between 0.14 Gy and 1.02 Gy of unintended dose.

Absorbed Dose: 0.1 to 1.0 Gy

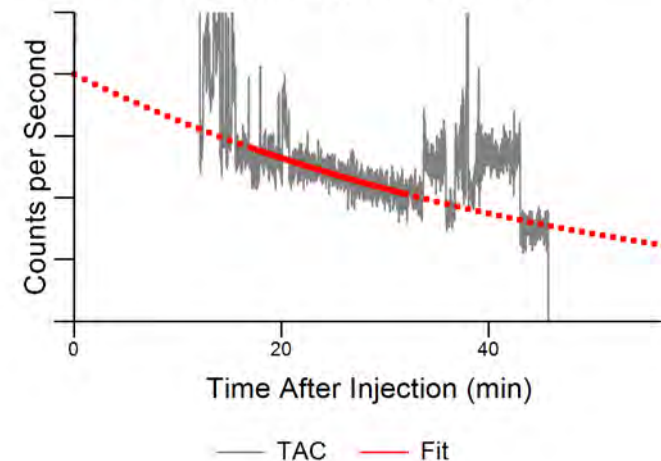
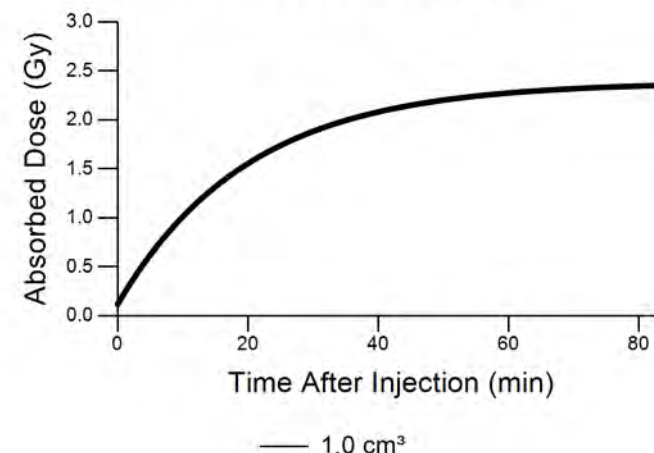
Scan #19527**Absorbed Dose: 2.4 Gy**

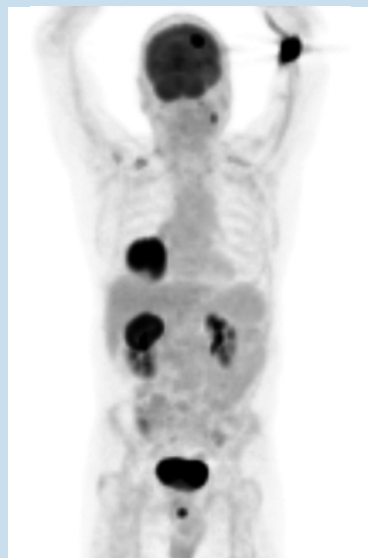Isotope	F-18
Injection Method	Manual, IV
Injection Location	R Antecubital
Injected Activity	5.00 mCi
Radiotracer Volume	1.00 mL
Saline Flush Volume	0.0 mL
Imaging Time	55.0 min
% Extravasation	28 %
Initial Activity	1.38 mCi
Imaging Time Activity	0.31 mCi
Reabsorption Rate	33.5 min
Dose Calculation Volume	1.00 cm ³
Dose Rate	84.4 mGy/mCi-min
Total Absorbed Dose	2.4 Gy

This patient was injected with 18F-FDG for a PET/CT scan as part of her breast cancer post-treatment assessment. The technologist prepared 9.17 mCi and performed an IV injection, which was then followed by a 20 mL saline flush.

After injecting, the technologist assayed the syringe and found 5 mCi remained within the syringe cap. She drew out the remaining activity and injected it as a straight stick.

The Lara time-activity curve for the initial 4.17 mCi injection showed no evidence of excess radiotracer at the injection site. The straight-stick injection of 5 mCi injection that followed resulted in excess radiotracer present at the injection site. Based on PET image measurements and the Lara time-activity data, we estimate that 1.4 mCi was infiltrated - resulting in approximately 2.4 Gy to 1 cm³ of tissue.

TAC with Exponential Fit**Cumulative Absorbed Dose**

Scan #19528**Absorbed Dose: 0.1 to 0.9 Gy**

Isotope	F-18
Injection Method	Manual, IV
Injection Location	L Antecubital
Injected Activity	13.00 mCi
Radiotracer Volume	1.50 mL
Saline Flush Volume	20.0 mL
Imaging Time	60.0 min
% Extravasation	5 %
Initial Activity	0.60 mCi
Imaging Time Activity	0.15 mCi
Reabsorption Rate	40.3 min
Dose Calculation Volume	1.00 to 21.00 cm ³
Dose Rate	84.4 to 4.7 mGy/mCi-min
Total Absorbed Dose	0.9 to 0.1 Gy

As part of an 18F-FDG study, this patient was injected in the right antecubital with 13 mCi. Additionally, the injection was flushed with 20 mL of saline.

Based on PET image measurements and dynamic time-activity data, the initial infiltration was estimated to be 0.6 mCi or 4.6%.

Using an initial infiltrated tissue volume of 1 cm³, absorbed dose was calculated to be 0.86 Gy. Assuming complete infiltration of the saline flush would decrease this dose to 0.11 Gy to 21 cm³ of tissue.

